

Fat Grafting to the Breast Revisited: Safety and Efficacy

Sydney R. Coleman, M.D.

Alesia P. Saboeiro, M.D.

New York, N.Y.

Background: A 1987 American Society of Plastic and Reconstructive Surgeons position paper predicted that fat grafting would compromise breast cancer detection and should therefore be prohibited. However, there is no evidence that fat grafting to breasts is less safe than any other form of breast surgery. As discussions of fat grafting to the breast are surfacing all over the world, it is time to reexamine the opinions of the 1987 American Society of Plastic and Reconstructive Surgeons position paper.

Methods: This is a retrospective examination of 17 breast procedures performed using fat grafting from 1995 to 2000. Indications included micromastia, postaugmentation deformity, tuberous breast deformity, Poland's syndrome, and postmastectomy reconstruction deformities. The technique used was the Coleman method of fat grafting, which attempts to minimize trauma and place grafted fat in small aliquots at many levels.

Results: All women had a significant improvement in their breast size and/or shape postoperatively and all had breasts that were soft and natural in appearance and feel. Postoperative mammograms identified changes one would expect after any breast procedure.

Conclusions: Given these results and reports of other plastic surgeons, free fat grafting should be considered as an alternative or adjunct to breast augmentation and reconstruction procedures. It is time to end the discrimination created by the 1987 position paper and judge fat grafting to the breast with the same caution and enthusiasm as any other useful breast procedure. (*Plast. Reconstr. Surg.* 119: 775, 2007.)

For over a century, surgeons have used autologous fat to enlarge and reshape breasts. In 1895, Czerny performed the first documented breast augmentation by transplanting a lipoma from the lumbar region to a breast defect.¹ In the early twentieth century, Lexer described placing a graft "as large as two fists" into a breast, with an excellent result 3 years later.² Others have described transplanting fat to the breast; however, none of the techniques ever became widely used. In the early 1980s, liposuction provided us with a new potential source of autologous tissue for breast augmentation, and surgeons soon described placement of the fatty tissue removed with liposuction into the breast.³⁻⁶

From the New York University School of Medicine.

Received for publication February 21, 2006; accepted July 18, 2006.

Presented at the American Association of Plastic Surgeons meeting, in Hilton Head, South Carolina, on May 9, 2006.

Copyright ©2007 by the American Society of Plastic Surgeons

DOI: 10.1097/01.prs.0000252001.59162.c9

After Mel Bircoll described his fat grafting at the California Society of Plastic Surgeons in 1985,^{3,4} a heated discussion over the safety of fat grafting to the breast ensued at regional and national meetings. In 1987, the American Society of Plastic and Reconstructive Surgeons Ad-Hoc Committee on New Procedures issued a position paper stating the following: "The committee is unanimous in deploring the use of autologous fat injection in breast augmentation [underlined in position paper]. Much of the injected fat will not survive, and the known physiological response to necrosis of this tissue is scarring and calcification. As a result, detection of early breast carcinoma through xerography and mammography will become difficult and the presence of disease may go undiscovered."⁷ These opinions, unsupported by any references or studies, made the injection of fat into a human breast taboo and tantamount to malpractice.

Ironically also in 1987, a retrospective study of the mammographic changes after breast reduction⁸ reported that calcifications were detectable in 50 percent of all mammograms more than 2 years from the time of surgery. Despite

this documented high incidence of calcifications, there was no discussion of discontinuing reduction mammoplasties because the procedure might interfere with breast cancer detection. It was well recognized by 1987 that with all surgical breast procedures, there is a risk of causing lumps and/or mammographic changes. The authors noted that a “confident differentiation between benign postoperative calcifications and carcinoma” could be made in most cases.⁸ Discussion had already begun in the literature concerning such problems after breast reduction^{9–11} and augmentation with silicone implants.^{12–14} Now, in 2006, radiologists can distinguish with a high level of confidence the calcifications that are a result of fat necrosis from calcifications that are related to breast cancers.^{15–25}

Because of the American Society of Plastic and Reconstructive Surgeons 1987 position paper, physicians have been hesitant to discuss fat grafting to the breast, creating a remarkable paucity of information on this topic. Despite the “veil of silence” that the position paper has imposed on the plastic surgery world, physicians are using grafted fat for augmentation and breast reconstruction. From France,^{26–28} Italy,^{29–31} China,³² Japan,³³ and even the United States,^{34,35} reports are surfacing of large series of patients treated safely over the last decades. Now, with recent scientific reports of the efficacy of fat grafting for breast reconstruction,^{26–30,33,36–38} the treatment of radiation damage to the chest,³⁰ reduction of breast capsular contracture,³⁰ and soft-tissue coverage of breast implants,^{30,31,34,36,39–41} it is time to reexamine the safety issues and efficacy of fat grafting to the breast.

PATIENTS AND METHODS

Patient Selection and Preparation

From November of 1995 to June of 2000, the senior author (S.R.C.) performed structural fat grafting to one or both breasts in 17 patients. Indications for fat grafting in these patients included micromastia (10 patients), postaugmentation deformity after removal of breast implants (one patient), postaugmentation deformity with breast implants (two patients), tuberous breast deformity (one patient), Poland’s syndrome (one patient), and postmastectomy reconstruction deformity (two patients). Ages ranged from 25 to 55 years, with a mean of 38.2 years.

All preoperative mammograms were negative for malignancy. Anesthesia was general (two patients) or epidural plus sedation with local infiltra-

tion and intercostal nerve blocks (15 patients). Fat was grafted in one to three stages, with an average of 278.6 cc of fat per operation per breast (Table 1).

All patients signed a separate consent form discussing potential complications of infiltrating fat into the breast and agreed to undergo routine postoperative mammography. It was emphasized to each patient that any palpable lump should never be assumed to be a result of the grafted fat until a complete workup had been performed.

Surgical Technique

The technique of structural fat grafting has been described previously by Coleman in detail.^{42–44} Fat was harvested using a 10-ml syringe attached to a two-hole Coleman harvesting cannula. After centrifugation and refinement, the fat was then transferred to 3-ml syringes. Blunt infiltration cannulas were used to place the fat through 2-mm incisions. Blunt cannulas not only allowed for more dispersion of the grafted tissue in small aliquots but also reduced the chance of intravascular injection.⁴⁵ At no time were sharp needles used for injection into the breast. The incisions were positioned to allow placement from at least two directions into each area grafted. Approximately 0.2 ml was placed with each withdrawal of the cannula.

Shaping of the breasts was accomplished by layering the fat into different levels until the desired contour was achieved. Although a breast implant augments by expanding the retromammary or retropectoral spaces, this technique allows selective augmentation and contouring from the chest wall to the skin. In most of the cases, the largest portion of the fat was infiltrated into the pectoralis major muscle, followed by the retropectoral and prepectoral spaces. Shaping of the breast was accomplished with placement subcutaneously into the superficial breast planes. Placement into the parenchyma of the breast was limited and was performed to further increase projection.

CASE REPORTS

Case 1

A 32-year-old woman presented with micromastia. A total of 190 cc was placed into the right breast and 245 cc was placed into the left breast. She has had no complications and an excellent cosmetic result after 7 years 6 months (Fig. 1).

Case 2

A 28-year-old woman presented with a bilateral tuberous breast deformity. A total of 380 cc was placed in the right and 370 cc was placed in the left breast. A second fat grafting procedure was performed 7 months later, in which a total of 340 cc was placed in the right breast and 300 cc was placed in

Table 1. Patient Summary

Patient	Age (yr)	Indication for Surgery	Amount Grafted (cc) per Operation		Follow-Up (mo)	Comments
			Right	Left		
1	32	Micromastia	190	245	90	Normal postoperative mammogram
2	28	Tuberous breasts	380	370	59	Normal postoperative mammogram
3	32	Postaugmentation deformity with implants; bony sternum	340	300	98	Local infection near silicone implant, resolved with I&D and antibiotics; the patient refused postoperative mammography
4	55	Deformity s/p explantation of silicone implants and capsulectomy	220	250	77	Siliconoma (1998), nodule-aspirated (fat necrosis) (1998), benign-appearing calcifications on mammography
5	46	Postmastectomy reconstruction deformity		71.5 77.5 211	58	Small nodule on mammography that was aspirated (fat necrosis)
6	41	Poland's syndrome	269.5		Phone only	Normal postoperative mammogram
7	41	Micromastia	440	397.5	79	Small nodules, benign-appearing calcifications on mammography
8	31	Micromastia	332	297	10	Benign-appearing calcifications on mammography
9	33	Postaugmentation deformity with implants	147.5	152.5	12	Breast cancer diagnosed on mammography
10	46	Micromastia	265.5	261.5	Phone only	Normal postoperative mammogram
11	43	Postmastectomy reconstruction deformity		224	Phone only	No postmastectomy mammogram because of mastectomy
12	33	Micromastia	287	289.5	54	Normal postoperative mammogram
13	39	Micromastia	357.5	295	Phone only	Normal postoperative mammogram
14	25	Micromastia	460	413	91	Benign-appearing calcifications
15	34	Micromastia	357.5	440	11	Normal postoperative mammogram
16	36	Micromastia	355	372.5	78	Normal postoperative mammogram
17	55	Micromastia	310	270	92	Breast cancer diagnosed on mammography

I&D, incision and drainage.

the left breast. She has had no complications postoperatively and has an excellent aesthetic result 4 years 11 months after the second procedure (Fig. 2).

Case 3

A 32-year-old woman presented with complaints that the medial portions of her breast implants were visible, which accentuated the "bony" appearance of her sternum. In addition, she felt that her breasts appeared to be too far apart. Refined fat was placed subcutaneously over the lateral sternum and medial breast bilaterally, 70 cc on the right and 50 cc on the left. Approximately 1 week postoperatively, she developed a local infection over the sternum that required drainage in the office. Cultures revealed *Staphylococcus aureus*, and she was placed on appropriate antibiotics, with subsequent resolution of the infection. Two years later, she had a small amount of fat (5 cc on the right and 8 cc on the left) injected into her inframammary breast scars in an attempt to improve the scars. No open procedures were performed, only fat grafting. She has maintained an excellent aesthetic result after 8 years 2 months from her original procedure (Fig. 3). In addition, her breasts have become softer and her capsular contracture has changed from a Baker grade III to a Baker grade I, making the shape of her breasts much more natural.

Case 4

A 55-year-old woman presented with a history of silicone gel breast augmentation in 1972. After having a ruptured implant

replaced in 1986, she had an exchange to saline-filled implants in 1994. After one of her saline implants ruptured, she presented seeking explantation of both implants and augmentation using fat grafting. In October of 1996, her saline implants were removed and bilateral capsulectomies were performed in preparation for fat grafting. In December of 1996, 220 cc was placed into the right breast and 250 cc was placed into the left. In April of 1998, she presented with a small, palpable nodule beneath the right areola that was aspirated and found to be suggestive of fat necrosis. On mammography, she had several small nodules in each breast that were submitted to biopsy and found to be consistent with silicone granulomas. A repeated mammogram obtained 6 months later revealed no abnormalities in either breast. In September of 1998, she had a second fat grafting with 290 cc of fat placed into the right breast and 250 cc placed into the left breast. Her most recent mammogram revealed only a benign-appearing calcification. She has maintained a significant improvement in the contour of her breasts after 6 years 5 months from the last fat grafting procedure (Fig. 4).

RESULTS

Table 1 is a summary of all of the patient data. Four patients were unable to return for follow-up but were contacted by phone a minimum of 12 months postoperatively (mean, 50.8

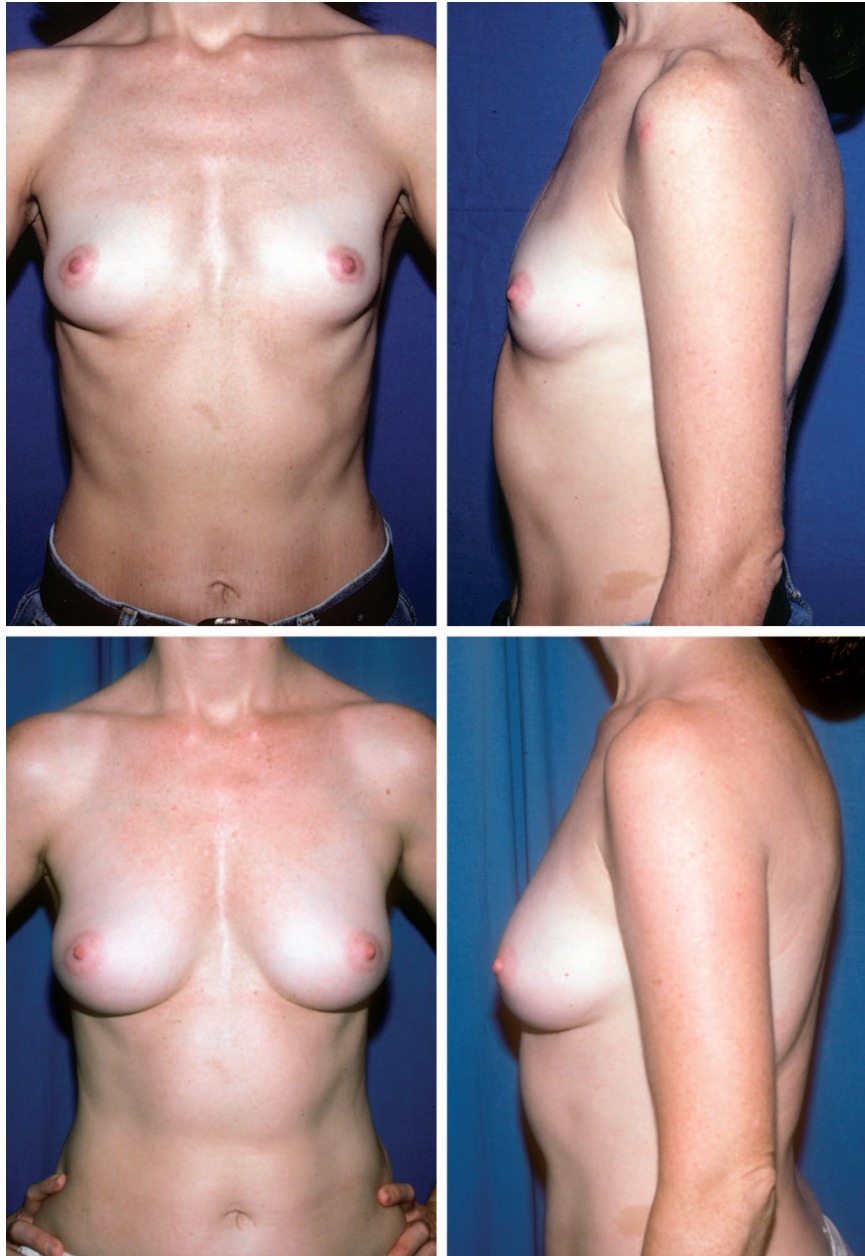

Fig. 1. (Above) Preoperative views of a 32 year-old woman with a complaint of micro-mastia. (Below) Postoperative views 7 years after one fat grafting procedure, with 245 cc grafted into the left breast and 190 cc into the right breast.

months) and reported having lasting, favorable results. The remaining 13 patients were followed in the office for a minimum of 10 months, with a mean follow-up of 62.2 months. All patients were pleased with their postoperative results, had a noticeable change in size, and had an improvement in the contour of their breasts. Of the patients who returned for photographic comparisons, all showed an enlargement of their breasts and improvement in the surface

contours. With this technique, corrections with as little as 50 to over 400 ml of fat grafted diffusely in the breast and surrounding tissues produced long-lasting results.

Immediately after the procedure, significant edema of the donor and recipient sites was present in all cases. By 4 to 6 months, the volume of the breast appeared to stabilize, with little apparent reduction in size over the ensuing years.

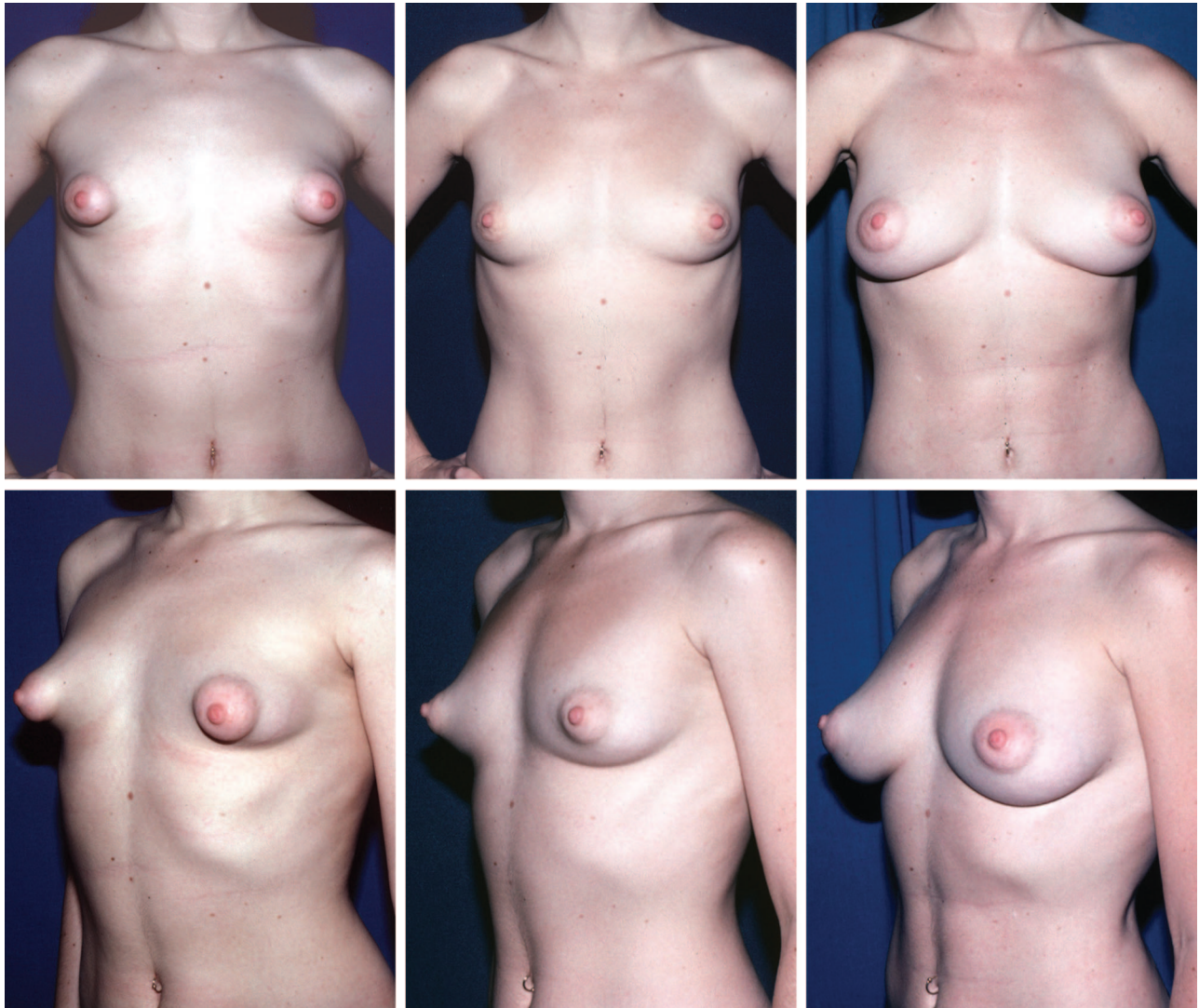


Fig. 2. (Left) Preoperative views of a 28-year-old woman with bilateral tuberous breast deformity. (Center) Views of the patient after the first fat grafting procedure, with 370 cc grafted into the left breast and 380 cc into the right. (Right) Postoperative views 4 years and 11 months after the second fat grafting, with placement of 300 cc into the left breast and 340 cc into the right breast.

The patient in case 3 developed a superficial *S. aureus* infection near her silicone implant, but her aesthetic result was not compromised. No other infections were noted. Two patients in this series were diagnosed with breast cancer using mammography. Cancer developed in one patient in an area that had not been grafted with fat. The second patient had correction of micromastia, and the cancer was discovered during a routine breast examination in an area that was probably infiltrated with fat. There was no reported delay in diagnosis or treatment. Both patients went on to have mastectomies and reconstruction.

Most patients underwent mammography sometime after 1 year (Table 1). One patient refused mammography (patient 3) and two were postmastectomy

patients. Four patients developed benign-appearing calcifications easily distinguishable from cancer, and three patients developed small nodules that revealed fat necrosis on aspiration. These abnormalities were similar to those described after breast reduction,^{8–10,21,46} breast reconstruction,^{18,22,23,47} and liposuction of the breast.^{16,24}

DISCUSSION

Technique

As with any surgical procedure, the technique used, the execution of the technique, and the experience of the surgeon affect the outcome. The technique must maximize survival of the fatty tissue, not only by minimizing trauma during har-

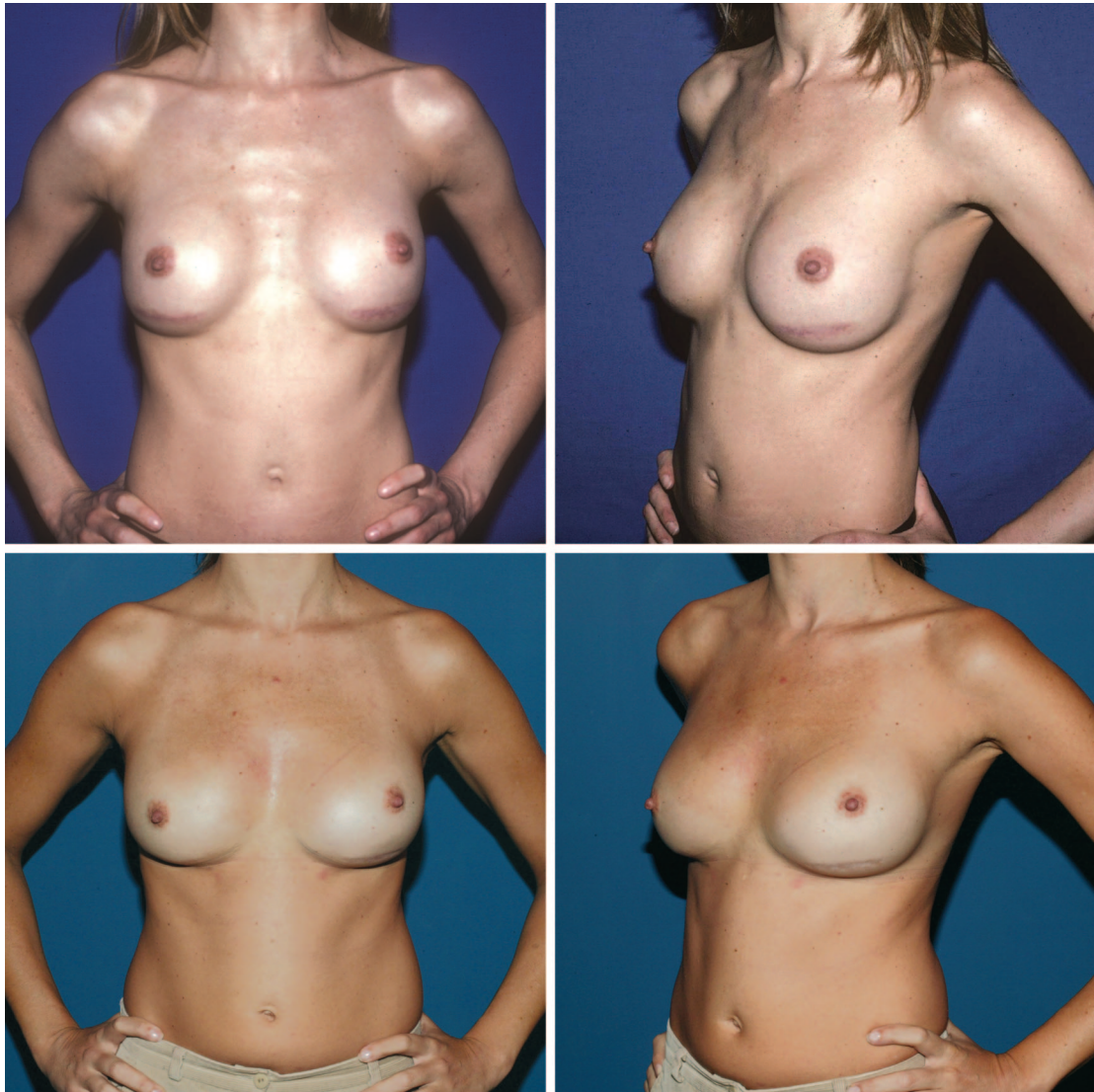

Fig. 3. (Above) Preoperative views of a 32-year-old woman with visible breast implants and a lack of soft-tissue coverage over her sternum. A total of 50 cc of fat was placed over the left implant edge onto the sternum and 70 cc was placed over the right. Two years later, fat was infiltrated into depressed inframammary scars (5 cc on the right and 8 cc on the left). (Below) Eight years and 2 months after the upper breast procedure and 6 years after the minor infiltration into the depressed lower breast scars, there was not only softening of the breast implant edges and sternum but also improvement in the bilateral capsular contracture and overall breast shape.

vesting and refinement but also by placing the living fatty tissue in small aliquots rather than large clumps. Minimizing the amount grafted with each pass of the cannula will maximize the surface area of contact between the grafted fat and the recipient tissue. The proximity of the newly grafted fat to a blood supply encourages survival and minimizes the potential for fat necrosis and later calcification.

In contrast, when fat is placed into the recipient site in large clumps, some of the fat cells may be too far from a blood supply. This can lead to fat

necrosis, causing not only lumps and calcifications but also the formation of liponecrotic cysts in the breasts.⁴⁸⁻⁵¹ Therefore, transplanting fat in large clumps should be avoided. The time to harvest, refine, and place fat into the breasts in this fashion will take many hours. In the patients in this series, placement of fatty tissue into the breasts took approximately 2 hours for the first 100 cc and approximately 45 minutes for each additional 100 cc placed.

The degree of sculpting possible with this technique is particularly obvious in the chal-

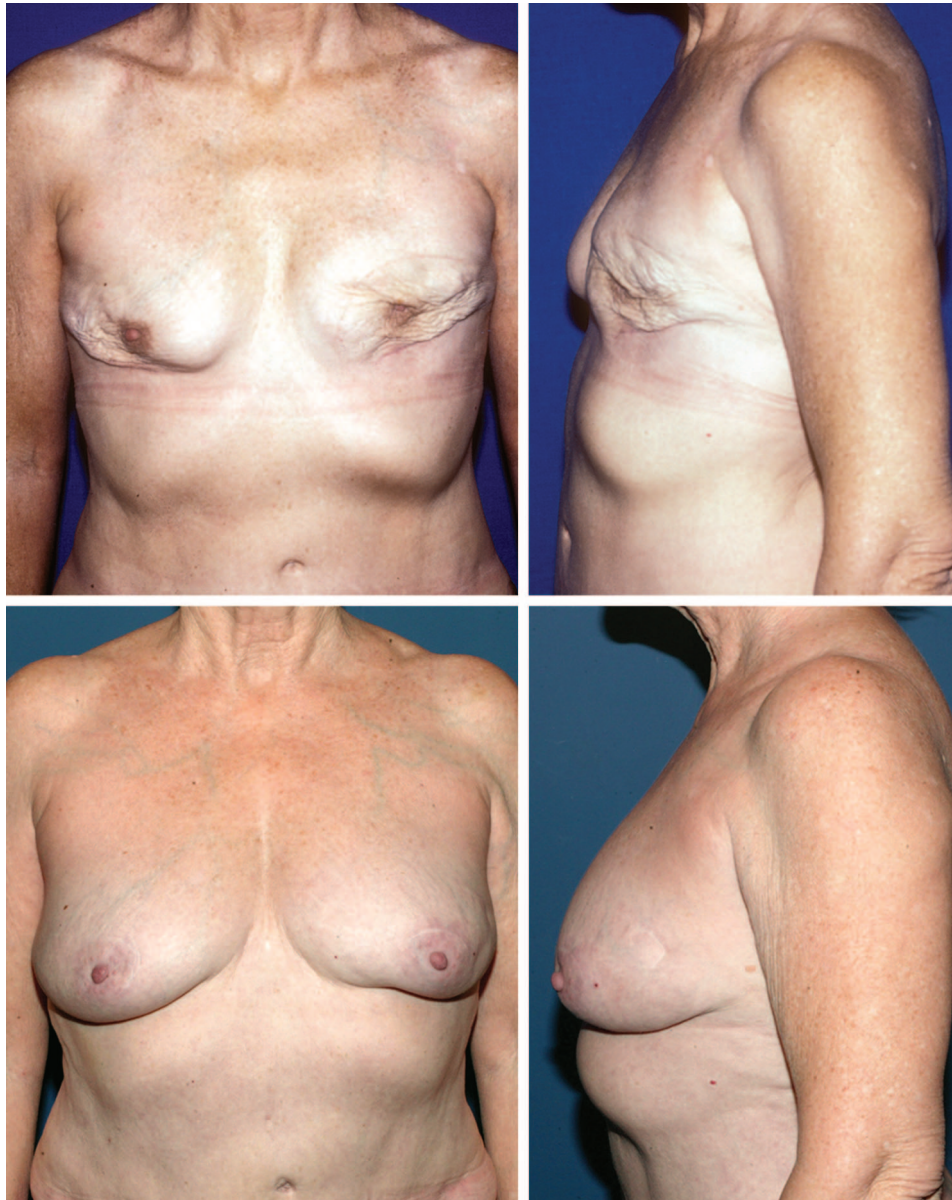


Fig. 4. (Above) Preoperative views of a 55-year-old woman with a significant deformity 4 months after removal of implants and capsulectomies. During the first fat grafting procedure, 250 cc of fat was placed into the left breast and 220 cc was placed into the right; 6 months after the first fat grafting, 250 cc more fat was placed into the left breast and 290 cc was placed into the right. The patient also underwent a left breast biopsy (note profiles) that revealed silicone granulomas. (Below) The patient returned at 6 years 5 months after the last fat grafting procedure pleased with the natural appearance of her breasts.

lenging correction of the tuberous breast deformity (Fig. 1). In this case, no fat was placed under the nipple-areola complex, and the skin envelope of the breast was selectively expanded with fat placed immediately beneath the skin. This changed the relative proportion of the breast to the areola, creating a more natural appearing and shapely breast. This type of

change was accomplished much more naturally and successfully with fat than if implants had been used.

The patients in this study with deformities resulting from their breast implants had inadequate soft-tissue coverage over the implants and obvious capsular contractures. Grafted fat can provide additional subcutaneous thickness to disguise visible

edges and wrinkling of implants and decrease the palpability of the underlying implant. In addition, the placement of fat around breast implants can result in a softening of the breast capsules, a finding also reported by Rigotti et al.³⁰

Limitations and Complications

The complications associated with fat grafting to the breast in the fashion described here seem to be similar to or less severe than those experienced with other breast procedures. With the use of minuscule incisions and the blunt nature of the technique, the possibility of damaging the underlying structures such as nerves, ducts, and blood vessels is significantly reduced. Fat tissue that is not perfused can die and result in necrotic cysts and even calcifications, but this can occur in any surgical breast procedure. An added benefit of this procedure is body contouring with the removal of fat.

However, even the surgeon who is facile at liposuction may create donor site deformities. Moreover, some patients simply do not have adequate donor sites. In these cases, a combination of fat grafting and implants may be more appropriate.

Fat grafting has advantages and disadvantages compared with implants. Breast augmentation using fat grafting is not associated with implant-related problems such as implant leakage or deflation, visible or palpable implants, or the development of breast capsular contracture.

However, there are several notable limitations to fat grafting to the breast. Breast augmentation using the technique described in this article is a much longer procedure, and the large volume changes commonly attained with implants are not possible using structural fat grafting. In this series, even with plentiful donor sites, the maximum change attained in one session of fat grafting was only one cup size. It is difficult to compare the effect of diffusely grafting fat to the change seen using an alloplastic implant. With structural fat grafting, fatty tissue is infiltrated diffusely throughout the breast and can be feathered into adjacent surrounding areas. Such thoroughly integrated and dispersed fullness does not translate into the same visual volume change as the localized change afforded by alloplastic implants. Volume magnetic resonance imaging studies or other volumetric studies may afford us with a more accurate quantification of the survival of a specific volume of fat placed into the breast.

Breast Cancer Detection

The most important consideration in plastic surgery is the safety of our patients. The lifetime

probability of a woman developing breast cancer has been estimated to be as high as one in seven.⁵² Detection and timely treatment of breast cancer are essential.

For 19 years, plastic surgeons have rejected fat grafting to the breast because of speculation that transplanted fat might die and cause lumps or calcifications that would interfere with breast cancer detection. There is no evidence that fat grafting should cause greater concern than any other breast procedure. Fat necrosis and calcifications occur in patients with every type of breast surgery: breast biopsy,^{11,16} implant procedures,⁵³⁻⁵⁸ radiation therapy,⁵⁹ breast reduction,^{21,24,60,61} breast reconstruction,^{18,22,25,47} and liposuction of the breast.²⁴ The incidence of calcifications after all types of breast operations varies but has been reported to be as high as 50 percent of patients after 2 years.⁸ Fortunately, radiologists are adept at distinguishing the calcifications of malignant causes from the benign calcifications resulting from fat necrosis.^{8,10,15-26,46}

An accurate incidence of calcifications after fat grafting to the breast remains to be determined by future studies. Fat placed even in small aliquots with each pass can necrose and develop small cysts and calcifications. However, breast cancer detection remains the safety issue, not the incidence of calcifications. Therefore, with fat grafting to the breast, as with any breast procedure, the patient must be counseled to undergo mammography on a regular basis and should be instructed on proper breast self-examination. Although mammography is favored among radiologists for differentiation of cancer from benign lesions of the breast, questionable lesions can also be imaged with ultrasound⁶²⁻⁶⁴ and magnetic resonance imaging.^{53,65} If there is a clinical suspicion or a radiographic abnormality that is indeterminate, a biopsy should always be performed.

Breast Cancer Therapy

Breast augmentation with fat grafting may allow the breast surgeon to consider conservative breast cancer procedures that alloplastic implants preclude. However, if a saline-filled or silicone gel-filled implant is present in a breast in which a cancer is detected, a lumpectomy may not be a good option. In previously augmented patients, aesthetic outcomes cannot be ensured without removing the implant and performing a mastectomy.⁶⁶⁻⁶⁹

Radiotherapy is a critical component of breast conservation treatment to reduce the incidence of

local recurrence.^{67,70,71} Unfortunately, radiotherapy of a breast with an implant remarkably increases the incidence of breast capsular contracture, infection, extrusion, and poor cosmetic result.^{67,69,72–75} With further studies and experience, fat grafting to the breast may provide a safer option for our patients than breast implants in terms of both cancer detection and cancer treatment.

Breast Reconstruction

After mastectomy, breast reconstruction with both autogenous flaps and with implants can still leave the patients noting subtle deformities and deficiencies, making their reconstructions seem incomplete.⁷⁶ Grafted fat can provide missing coverage^{30,34,39,40} and may relax the breast capsule,³⁰ as demonstrated in the patient in case 3. It can be grafted in either large or small volumes to correct otherwise difficult problems^{28,31,36} such as axillary deficiencies, poor breast shape, visible implant edges, capsular contracture, and even radiation damage.³⁰ In fact, Delay et al. reported fat grafting to be among the most significant advances of prosthetic breast surgery.²⁷

CONCLUSIONS

The only conclusion that can be drawn from such a small study is that remarkable, long-lasting, natural improvements in the size and shape of a breast are possible with a specific technique of fat grafting. When harvested and refined with minimal trauma and when placed in small aliquots, the transplanted free fat grafts can remain viable and provide a structure and shape to the breast that cannot be achieved with implants alone or with other types of surgery.

After fat grafting to the breast, fat necrosis will sometimes occur, calcifications or cysts will occasionally result, and lumps will sometimes be palpable, as with every other surgical manipulation of the breast. The exact incidence of calcifications after fat grafting to the breasts remains to be determined, but the postoperative mammographic changes are similar to those seen with other breast procedures. In any event, microcalcifications are not the problem; missing a cancer is the potential problem after any surgical procedure to the breast. Therefore, the same vigilance that is used for monitoring our patients after any breast procedure should be followed after fat grafting to a breast.

Autologous fat grafting to the breast can be used for simple aesthetic augmentation of the

breast, correction of breast asymmetry, correction of breast deformities, as an adjunct or primary tool in breast reconstruction, and for soft-tissue coverage of breast implants. Fat grafting using this technique appears to be as safe as and perhaps even more effective than many other methods of changing the contour of the breast. Further prospective analysis will be necessary to better define the indications and results of this technique.

One hundred years ago, Halsted denounced breast reconstruction because it might interfere with the detection of local recurrences or even cause the progression of breast cancer.⁷⁷ Because of Halsted, breast reconstruction was taboo in the United States for decades. However, with advances in breast surgery and radiography, breast reconstruction has become the standard of care following breast cancer procedures.

Nineteen years ago, one American committee decided that surgeons worldwide should not graft fat to the breast because fat grafting might do something that every other surgical procedure to the breast does—cause scarring or calcifications. The unsupported opinions and statements of the authors of the 1987 American Society of Plastic and Reconstructive Surgeons position paper on fat transplantation⁷ created a double standard, whereby fat grafting to the breast was singled out to be dangerous for possessing the same limitations as every surgical breast procedure. This American declaration censored worldwide discussion of fat grafting to the breast from 1987 until 2005 and denied surgeons and women the consideration of this autologous, potentially more efficacious alternative and adjunct to many breast procedures. It is time to end the prohibition of fat grafting to the breast created by the 1987 position paper. We should judge fat grafting to the breast with the same caution and enthusiasm that we do with all other breast procedures.

Sydney R. Coleman, M.D.

New York University School of Medicine
44 Hudson Street
New York, N.Y. 10013
lipostructure@yahoo.com

DISCLOSURES

Sydney R. Coleman, M.D., receives royalties from Byron Medical, Inc.. Alesia P. Saboeiro, M.D., has no financial interests to disclose.

REFERENCES

1. Czerny, V. Plastischer Ersatz der Brustdruse durch ein Lipom. *Zentralbl. Chir.* 27: 72, 1895.
2. Hinderer, U. T., and Del Rio, J. L. Erich Lexer's mammaplasty. *Aesthetic Plast. Surg.* 16: 101, 1992.

3. Bircoll, M. Cosmetic breast augmentation utilizing autologous fat and liposuction techniques. *Plast. Reconstr. Surg.* 79: 267, 1987.
4. Bircoll, M., and Novack, B. H. Autologous fat transplantation employing liposuction techniques. *Ann. Plast. Surg.* 18: 327, 1987.
5. Matsudo, P. K., and Toledo, L. S. Experience of injected fat grafting. *Aesthetic Plast. Surg.* 12: 35, 1988.
6. Fournier, P. F. The breast fill. In *Liposculpture: The Syringe Technique*. Paris: Arnette-Blackwell, 1991. Pp. 357–367.
7. ASPRS Ad-Hoc Committee on New Procedures. Report on autologous fat transplantation, September 30, 1987.
8. Brown, F. E., Sargent, S. K., Cohen, S. R., et al. Mammographic changes following reduction mammoplasty. *Plast. Reconstr. Surg.* 80: 691, 1987.
9. Isaacs, G., Rozner, L., and Tudball, C. Breast lumps after reduction mammoplasty. *Ann. Plast. Surg.* 15: 394, 1985.
10. Miller, C. L., Feig, S. A., and Fox, J. W. T. Mammographic changes after reduction mammoplasty. *A.J.R. Am. J. Roentgenol.* 149: 35, 1987.
11. Sickles, E. A., and Herzog, K. A. Mammography of the post-surgical breast. *A.J.R. Am. J. Roentgenol.* 136: 585, 1981.
12. Redfern, A. B., Ryan, J. J., and Su, T. C. Calcification of the fibrous capsule about mammary implants. *Plast. Reconstr. Surg.* 59: 249, 1977.
13. Benjamin, J. L., and Guy, C. L. Calcification of implant capsules following augmentation mammoplasty: Case report. *Plast. Reconstr. Surg.* 59: 432, 1977.
14. Koide, T., and Katayama, H. Calcification in augmentation mammoplasty. *Radiology* 130: 337, 1979.
15. Kneeshaw, P. J., Lowry, M., Manton, D., et al. Differentiation of benign from malignant breast disease associated with screening detected microcalcifications using dynamic contrast enhanced magnetic resonance imaging. *Breast* 15: 29, 2006.
16. Chala, L. F., De Barros, N., De Camargo Moraes, P., et al. Fat necrosis of the breast: Mammographic, sonographic, computed tomography, and magnetic resonance imaging findings. *Curr. Probl. Diagn. Radiol.* 33: 106, 2004.
17. Jiang, Y., Metz, C. E., Nishikawa, R. M., et al. Comparison of independent double readings and computer-aided diagnosis (CAD) for the diagnosis of breast calcifications. *Acad. Radiol.* 13: 84, 2006.
18. Kim, S. M., and Park, J. M. Mammographic and ultrasonographic features after autogenous myocutaneous flap reconstruction mammoplasty. *J. Ultrasound Med.* 23: 275, 2004.
19. Fischer, U., Baum, F., Obenauer, S., et al. Comparative study in patients with microcalcifications: Full-field digital mammography vs screen-film mammography. *Eur. Radiol.* 12: 2679, 2002.
20. Yunus, M., Ahmed, N., Masroor, I., et al. Mammographic criteria for determining the diagnostic value of microcalcifications in the detection of early breast cancer. *J. Pak. Med. Assoc.* 54: 24, 2004.
21. Danikas, D., Theodorou, S. J., Kokkalis, G., et al. Mammographic findings following reduction mammoplasty. *Aesthetic Plast. Surg.* 25: 283, 2001.
22. Leibman, A. J., Styblo, T. M., and Bostwick, J., III. Mammography of the postreconstruction breast. *Plast. Reconstr. Surg.* 99: 698, 1997.
23. Hogge, J. P., Robinson, R. E., Magnant, C. M., et al. The mammographic spectrum of fat necrosis of the breast. *Radiographics* 15: 1347, 1995.
24. Abboud, M., Vadoud-Seyedi, J., De Mey, A., et al. Incidence of calcifications in the breast after surgical reduction and liposuction. *Plast. Reconstr. Surg.* 96: 620, 1995.
25. Mendelson, E. B. Evaluation of the postoperative breast. *Radiol. Clin. North Am.* 30: 107, 1992.
26. Pierrefeu-Lagrange, A. C., Delay, E., Guerin, N., et al. Radiological evaluation of breasts reconstructed with lipomodelling (in French). *Ann. Chir. Plast. Esthet.* 51: 18, 2005.
27. Delay, E., Delpierre, J., Sinna, R., et al. How to improve breast implant reconstructions (in French). *Ann. Chir. Plast. Esthet.* 50: 582, 2005.
28. Delay, E., Delaporte, T., and Sinna, R. Breast implant alternatives (in French). *Ann. Chir. Plast. Esthet.* 50: 652, 2005.
29. Zocchi, M. L., Zuliani, F., Nava, M., et al. Bicompartimental breast lipostructuring. Presented at the 7th International Congress of Aesthetic Medicine, Milan, Italy, October 13–15, 2005.
30. Rigotti, G., Marchi, A., Galiè, M., et al. Clinical treatment of radiotherapy tissue damages by lipoaspirates transplant: A healing process mediated by adipose derived stem cells (ASCS). *Plast. Reconstr. Surg.* Accepted for publication.
31. Grisotti, A. Lipostructure, of course in the body and breast. Presented at the American Alpine Workshop in Plastic Surgery 17th Annual Meeting, Sun Valley, Idaho, February 12–17, 2006.
32. Wang, Y., Qi, K., Ma, Y., et al. Fat particle injection auto-transplantation: A 10-year review (in Chinese). *Chin. J. Plast. Surg.* 18: 95, 2002.
33. Yoshimura, K., Matsumoto, D., and Gonda, K. A clinical trial of soft tissue augmentation by lipoinjection with adipose-derived stromal cells (ASCS). Presented at the International Fat Applied Technology Society Third Annual Meeting, Charlottesville, Virginia, September 11–14, 2005.
34. Teimourian, B. Spreading the wealth: Large volume fat distribution to breast and face from thighs and legs. Presented at the American Alpine Workshop in Plastic Surgery 17th Annual Meeting, Sun Valley, Idaho, February 12–17, 2006.
35. Fulton, J. E. Breast contouring with “gelled” autologous fat: A 10-year update. *Int. J. Cosmet. Surg. Aesthetic Dermatol.* 5: 155, 2003.
36. Spear, S. L., Wilson, H. B., and Lockwood, M. D. Fat injection to correct contour deformities in the reconstructed breast. *Plast. Reconstr. Surg.* 116: 1300, 2005.
37. Nava, M. La definizione del profilo superiore della mammella ricostruita. Presented at the 30th Anniversary Course of the Foundation of G. Sanvenero Rosselli, Milan, Italy, September 16, 2005.
38. Berrino, P. La ricostruzione mammaria. Presented at the 30th Anniversary Course of the Foundation of G. Sanvenero Rosselli, Milan, Italy, September 16, 2005.
39. Holle, J. Lipofilling in rhinoplasty and breast augmentation. Presented at the American Alpine Workshop in Plastic Surgery 17th Annual Meeting, Sun Valley, Idaho, February 12–17, 2006.
40. Massiha, H. Scar tissue flaps for the correction of postimplant breast rippling. *Ann. Plast. Surg.* 48: 505, 2002.
41. Baruffaldi-Preis, F. La correzione delle depressioni: Esiti cicatriziali e rippling. Presented at the 30th Anniversary Course of the Foundation of G. Sanvenero Rosselli, Milan, Italy, September 16, 2005.
42. Coleman, S. R. Hand rejuvenation with structural fat grafting. *Plast. Reconstr. Surg.* 110: 1731, 2002.
43. Coleman, S. R. *Structural Fat Grafting*. St. Louis, Mo.: Quality Medical, 2004. Pp. 30–175.
44. Coleman, S. R. Structural fat grafting. In F. Nahai (Ed.), *The Art of Aesthetic Surgery: Principles & Techniques*. St. Louis, Mo.: Quality Medical, 2005. Pp. 289–363.
45. Coleman, S. R. Avoidance of arterial occlusion from injection of soft tissue fillers. *Aesthetic Surg. J.* 22: 555, 2002.

46. Mitnick, J. S., Roses, D. F., Harris, M. N., et al. Calcifications of the breast after reduction mammoplasty. *Surg. Gynecol. Obstet.* 171: 409, 1990.
47. Eidelman, Y., Liebling, R. W., Buchbinder, S., et al. Mammography in the evaluation of masses in breasts reconstructed with TRAM flaps. *Ann. Plast. Surg.* 41: 229, 1998.
48. Castello, J. R., Barros, J., and Vazquez, R. Giant liponecrotic pseudocyst after breast augmentation by fat injection. *Plast. Reconstr. Surg.* 103: 291, 1999.
49. Maillard, G. F. Liponecrotic cysts after augmentation mammoplasty with fat injections. *Aesthetic Plast. Surg.* 18: 405, 1994.
50. Montanana Vizcaino, J., Baena Montilla, P., and Benito Ruiz, J. Complications of autografting fat obtained by liposuction. *Plast. Reconstr. Surg.* 85: 638, 1990.
51. Kwak, J. Y., Lee, S. H., Park, H. L., et al. Sonographic findings in complications of cosmetic breast augmentation with autologous fat obtained by liposuction. *J. Clin. Ultrasound* 32: 299, 2004.
52. Gloeckler Ries, L. A., Reichman, M. E., Lewis, D. R., et al. Cancer survival and incidence from the Surveillance, Epidemiology, and End Results (SEER) program. *Oncologist* 8: 541, 2003.
53. Huch, R. A., Kunzi, W., Debatin, J. F., et al. MR imaging of the augmented breast. *Eur. Radiol.* 8: 371, 1998.
54. Handel, N., Jensen, J. A., Black, Q., et al. The fate of breast implants: A critical analysis of complications and outcomes. *Plast. Reconstr. Surg.* 96: 1521, 1995.
55. Leibman, A. J. Imaging of complications of augmentation mammoplasty. *Plast. Reconstr. Surg.* 93: 1134, 1994.
56. Leibman, A. J., and Kruse, B. D. Imaging of breast cancer after augmentation mammoplasty. *Ann. Plast. Surg.* 30: 111, 1993.
57. Raso, D. S., Greene, W. B., Kalasinsky, V. F., et al. Elemental analysis and clinical implications of calcification deposits associated with silicone breast implants. *Ann. Plast. Surg.* 42: 117, 1999.
58. Fodor, J., Udvarhelyi, N., Gulyas, G., et al. Ossifying calcification of breast implant capsule. *Plast. Reconstr. Surg.* 113: 1880, 2004.
59. Cyslak, D., and Carpenter, P. M. Breast imaging case of the day: Fat necrosis of the breast. *Radiographics* 19: S80, 1999.
60. Netscher, D., Meade, R. A., Friedman, J. D., et al. Mammography and reduction mammoplasty. *Aesthetic Surg. J.* 19: 445, 1999.
61. Mandrekas, A. D., Assimakopoulos, G. I., Mastorakos, D. P., et al. Fat necrosis following breast reduction. *Br. J. Plast. Surg.* 47: 560, 1994.
62. Fine, R. E., and Staren, E. D. Updates in breast ultrasound. *Surg. Clin. North Am.* 84: 1001, 2004.
63. Chen, S. C., Cheung, Y. C., Su, C. H., et al. Analysis of sonographic features for the differentiation of benign and malignant breast tumors of different sizes. *Ultrasound Obstet. Gynecol.* 23: 188, 2004.
64. Ganott, M. A., Harris, K. M., Ilkhanipour, Z. S., et al. Augmentation mammoplasty: Normal and abnormal findings with mammography and US. *Radiographics* 12: 281, 1992.
65. Reddy, D. H., and Mendelson, E. B. Incorporating new imaging models in breast cancer management. *Curr. Treat. Options Oncol.* 6: 135, 2005.
66. Handel, N. Surgical treatment of breast cancer in previously augmented patients (Discussion). *Plast. Reconstr. Surg.* 111: 1084, 2003.
67. Karanas, Y. L., Leong, D. S., Da Lio, A., et al. Surgical treatment of breast cancer in previously augmented patients. *Plast. Reconstr. Surg.* 111: 1078, 2003.
68. Handel, N. Conservation therapy for breast cancer following augmentation mammoplasty. *Plast. Reconstr. Surg.* 104: 867, 1999.
69. Handel, N., Lewinsky, B., Jensen, J. A., et al. Breast conservation therapy after augmentation mammoplasty: Is it appropriate? *Plast. Reconstr. Surg.* 98: 1216, 1996.
70. Fisher, B., Anderson, S., Bryant, J., et al. Twenty-year follow-up of a randomized trial comparing total mastectomy, lumpectomy, and lumpectomy plus irradiation for the treatment of invasive breast cancer. *N. Engl. J. Med.* 347: 1233, 2002.
71. Holli, K., Saaristo, R., Isola, J., et al. Lumpectomy with or without postoperative radiotherapy for breast cancer with favourable prognostic features: Results of a randomized study. *Br. J. Cancer* 84: 164, 2001.
72. Vandeweyer, E., and Deraemaeker, R. Radiation therapy after immediate breast reconstruction with implants. *Plast. Reconstr. Surg.* 106: 56, 2000.
73. Spear, S. L., and Onyewu, C. Staged breast reconstruction with saline-filled implants in the irradiated breast: Recent trends and therapeutic implications. *Plast. Reconstr. Surg.* 105: 930, 2000.
74. Evans, G. R., Schusterman, M. A., Kroll, S. S., et al. Reconstruction and the radiated breast: Is there a role for implants? *Plast. Reconstr. Surg.* 96: 1111, 1995.
75. Mark, R. J., Zimmerman, R. P., and Greif, J. M. Capsular contracture after lumpectomy and radiation therapy in patients who have undergone uncomplicated bilateral augmentation mammoplasty. *Radiology* 200: 621, 1996.
76. Andrade, W. N., and Semple, J. L. Patient self-assessment of the cosmetic results of breast reconstruction. *Plast. Reconstr. Surg.* 117: 44, 2006.
77. Uroskie, T. W., and Colen, L. B. History of breast reconstruction. *Semin. Plast. Surg.* 18: 65, 2004.