

# ALL ABOUT HANDS

*Structural fat grafting does more than fill; it also rejuvenates and thickens skin*

John Jesitus

SENIOR STAFF CORRESPONDENT

In hand rejuvenation, fat grafting performs long-term skin thickening and rejuvenating functions far beyond its initial filling effect, says Sydney R. Coleman, M.D., a New York plastic and reconstructive surgeon in private practice.

"People wonder why we're putting fat in the hand," Dr. Coleman says. Normally, after childhood, "There's little if any fat in the hand. But we're learning now that aging has a lot to do with atrophy," he says.



Dr. Coleman

Dr. Coleman says that initially, "I approached the hands by restoring fullness to them, which undoubtedly is a component in reversing aging. However, hand rejuvenation isn't just filling, if it involves changing the quality of the skin."

In particular, he says that the hand of a person age 16 to 25 appears soft and has thicker skin than older hands do. Additionally, "Healthy, athletic hands have visible veins," with as much as 50 to 60 percent of the vein circumference protruding. "But as we age, the skin gets much thinner," which makes veins, joints and tendons much more obvious, he adds.

More than a decade ago, researchers discovered that fat contains a high quantity of mesenchymal stem cells whose

functions include repairing tissues, improving blood supply and preventing or even reversing scarring, Dr. Coleman says. "These are almost exactly the same stem cells found in bone marrow."

Subsequent investigators showed in an animal model that injecting fat under normal skin thickened the skin as much as 100 percent, due most likely to neocollagenesis at the recipient site (Mojallal A, Lequeux C, Shipkov C, et al. *Plast Reconstr Surg.* 2009;124(3):765-774). "That's probably the more important aspect in dorsal hand rejuvenation — not just filling, but thickening the skin and rejuvenating it," he says.

**HOW IT'S DONE** One patient Dr. Coleman treated in this fashion was a 52-year-old female with arthritis and wasting between the fingers that made her hands look much older than she was. "I injected 26 cc over the back of each hand, up to the middle joint of each finger. There are veins going up that far. And if you don't go that far out on the fingers, the rest of the hand suddenly looks better, but the fingers don't," he says.

A typical patient receives 25 cc to 35 cc per hand. "It sounds like a lot, and on the face, it would be," he adds. "But to the back of the hand, it's just a very thin layer." Dr. Coleman says he usually starts injecting at the fingers then works his way down the back of the hand past the wrist.

Typically, Dr. Coleman injects through seven or eight puncture-like incisions



per hand. "I used to use a knife, but now I use a large needle to make the incision sites," he says. "And I place the fat entirely against the skin. I don't inject anything deep, so I'm staying between the skin, and the veins and tendons."

Additionally, he says that to prevent entering and injecting arteries, which could cause not only bleeding and bruising but also a pulmonary or arterial embolus, he uses only blunt cannulas — typically 17 or 18 gauge, and 19 gauge in the fingers.

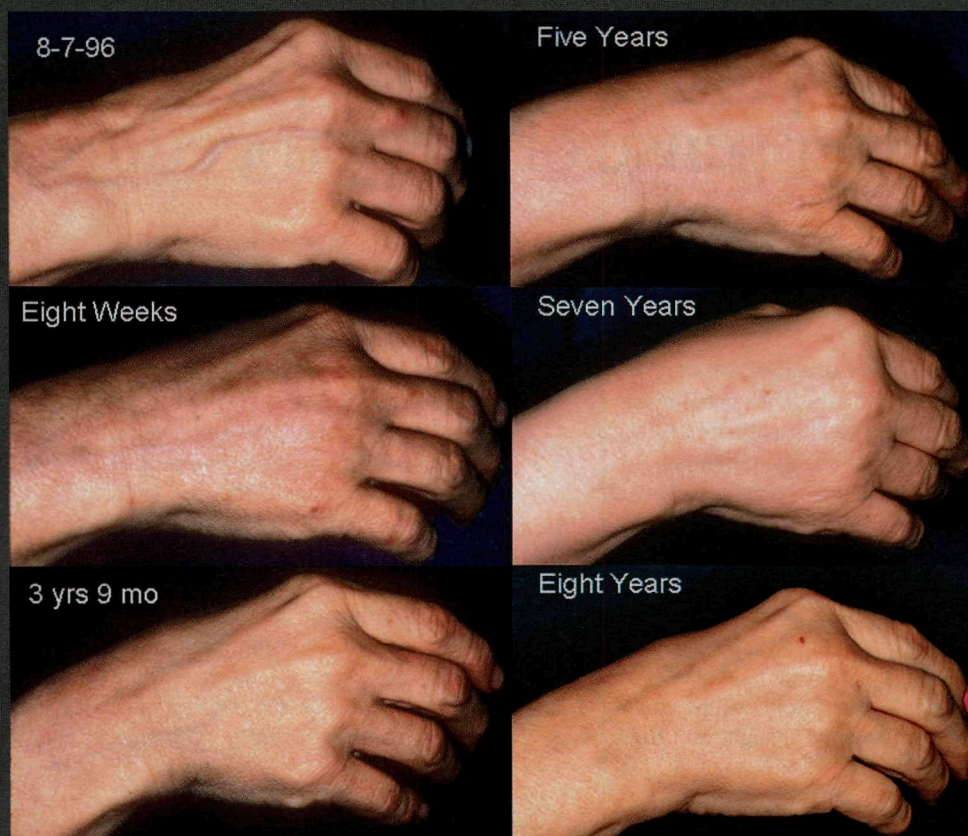
Along with preserving veins and arteries, Dr. Coleman says, blunt cannulas provide more stable results. "Cutting a swath in the tissue with a sharp needle destabilizes the tissue, whereas if you're pushing a blunt cannula through, the cannula goes through the natural tissue planes." That way, he says that when the cannula is withdrawn, the tissues fall back into their natural plane.

Because this approach creates minimal tissue disruption, it allows one to inject more fat, and it's less likely to move than it would if injected via sharp needle," Dr. Coleman says. It's also important, he says, to weave the fat into the subcutaneous layer with multiple passes, using the blunt cannula to place miniscule amounts of fatty tissue with each pass (Coleman SR. *Plast Reconstr Surg.* 2002;110(7):1731-1744; discussion 1745-1747).

**POSTSURGICAL CARE** For postsurgical dressing, Dr. Coleman says he places two layers of microfilm tape over the back of the hand. Although this may decrease swelling somewhat, he says the main reason for the microfilm tape is to prevent patients from sleeping on their hands or touching them too much. "I used to tell patients to apply cold compresses, but we now have evidence showing that cold kills fat," he says. He removes the tape after four or five days, at the same time he's removing sutures.

Five days postsurgery, patients typically experience swelling, but no bruising, Dr. Coleman says. "If you're not using sharp needles or cutting anything, usually those blood vessels are big enough to roll off the cannula. I rarely see bruising, and at five days, the incision sites are hard to locate."

The surgeon's goal when using the procedure is to create an integrated layer of fat that looks and feels like thicker skin, and a slight increase in subcutaneous fullness, Dr. Coleman says.



A 42-year-old female patient before (top left) and at various time points after fat grafting. (Photos credit: Sydney R. Coleman, M.D.)

Moreover, he says he likes to concentrate the fat before injection because doing so can double the number of stem cells it contains.

When fat is processed via centrifuge, the portion containing the most water sinks to the bottom of the test tube, while the oiliest portion rises to the top, he says. Even after removing the oil and water, the fat in those two areas approximates the density of oil or water. "By using the denser fat, you're using fat that contains more stem cells and growth factors (Pu LL, Coleman SR, Cui X, et al. *Plast Reconstr Surg.* 2008;122(3):932-937)," he says.

Most patients look better two weeks posttreatment, "But it's mainly from puffiness," Dr. Coleman says. "With time, the quality of the skin improves. The wrinkles don't necessarily go away, but they soften, and the skin looks healthier. Also, the tendons and veins become less obvious."

With a 42-year-old female patient he treated, says Dr. Coleman, a close-up photo taken eight weeks post-treatment showed that a prominent vein was still visible. At three years post-treatment, however, "The vein was almost completely gone. I believe that's because the skin overlying the vein had a chance to thicken significantly." At a five-year follow-up visit, this patient's hands showed significant wrinkle remodeling, which continued to improve through seven-year and eight-year follow-up visits. "There's a progressive improvement — it doesn't happen all at once," he says.

**MOVING ONTO THE FIELD** Dr. Coleman says that results he achieved through fat grafting in another 42-year-old female patient with severe

chemical burns on her hands helped initiate a study funded by the U.S. Department of Defense to treat soldiers who have suffered burn wounds. For this patient, he injected 32.5 cc into the left hand and 25 cc into the right, extending well into the forearm area on both arms.

Postsurgical photos of this patient showed that between six weeks and four months, ropey scarring on the back of her hands flattened, although uneven pigment resulting from scarring remained. "But between four months and three years, there was a remarkable softening of the back of the hand," he says, resulting in even pigmentation and little ropiness.

Recently, this patient returned nearly 16 years postsurgery. At this point, "She'd all but forgotten about the chemical burns on her hands — she was here for facial fat grafting treatment. I took pictures of her hands, and the skin is almost normal," Dr. Coleman says.

Typically, post-treatment fullness stabilizes at two to four months, Dr. Coleman says. Also at around two months postsurgery, other changes — including color improvements, skin thickening, wrinkle reduction and scar softening or elimination — begin. Therefore, "Fat grafting does much more than fill. It repairs and rejuvenates the overlying skin over a long period of time. This type of regeneration is a new consideration for hand rejuvenation." ◀

**Disclosures:** Dr. Coleman is a consultant for and receives royalties from Mentor, which manufactures a line of cannulas he designed.